Groupe Hospitalier RANGUEIL-LARREY

Hôpitaux de Toulouse

Université de Toulouse

IMAGERIES NOUVELLES POUR LA PRATIQUE

EXEMPLE DES ATTEINTES CORONAIRES DANS LA STÉNOSE AORTIQUE

Ateliers d'imagerie du CNCF

IRM ET MYOCARDE

QUELLES INFORMATIONS EN ATTENDRE ?

Olivier LAIREZ
CHU de Toulouse

Liens d'intérêt

Olivier LAIREZ

Aucun

Role of advanced left ventricular imaging in adults with aortic stenosis

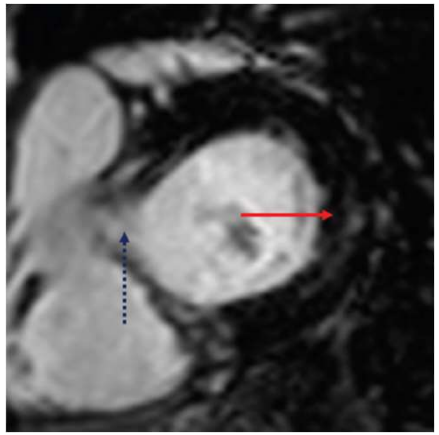

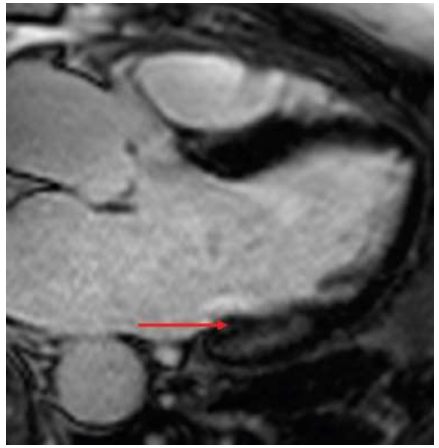

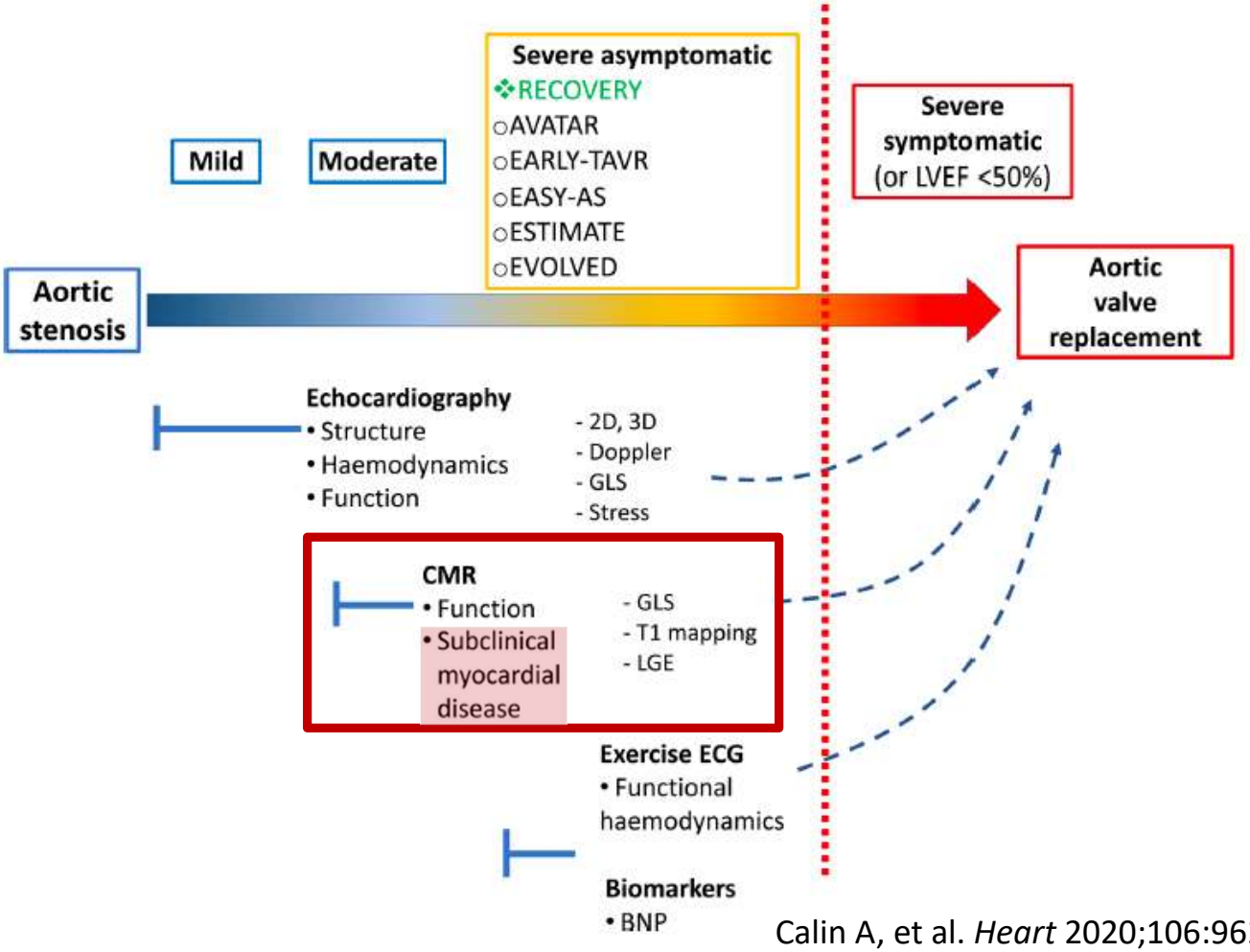

Calin A, et al. *Heart* 2020;106:962–969

Hôpitaux de Toulouse

PLACE DU 4D FLOW

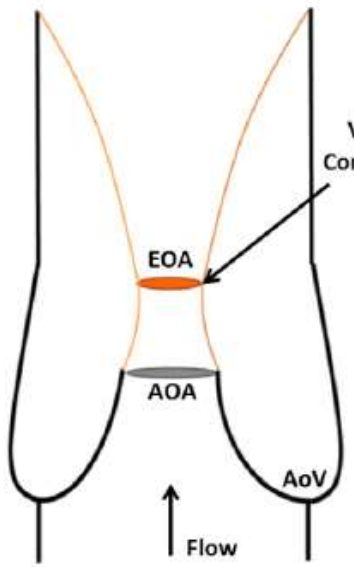

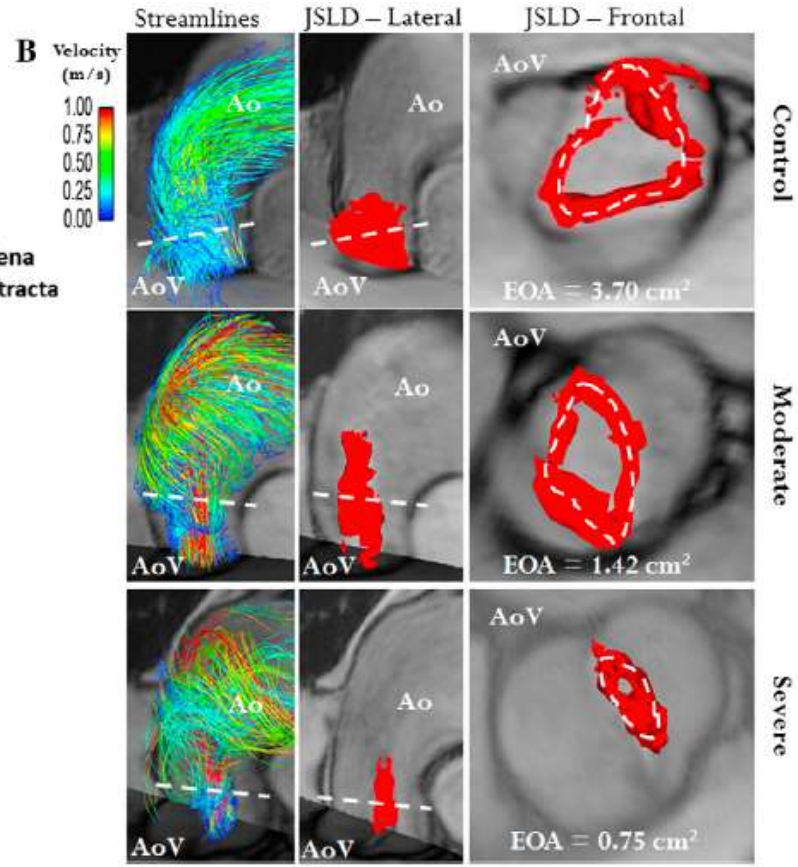

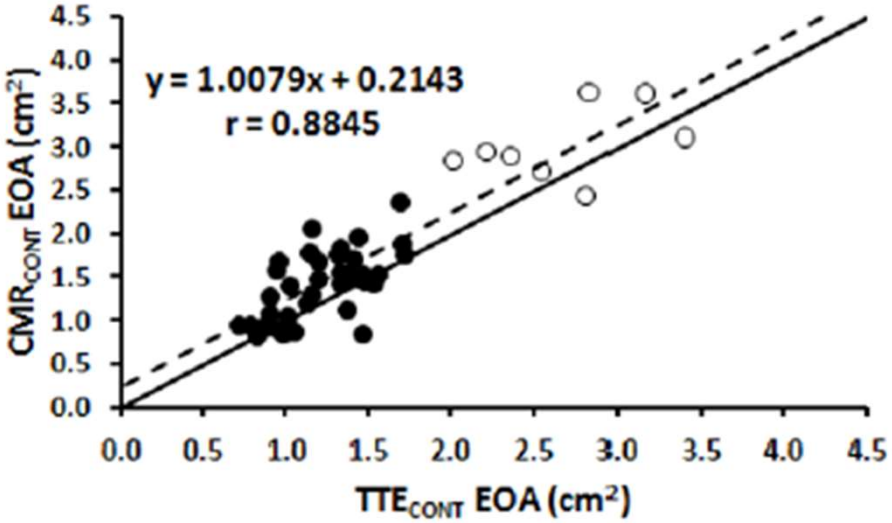

Hôpitaux de Toulouse

Garcia J, et al. *Magn Reson Imaging.* 2014;32:891-8

Garcia J, et al. *J Cardiovasc Magn Reson.* 2012;14:23

PLACE DU 4D FLOW

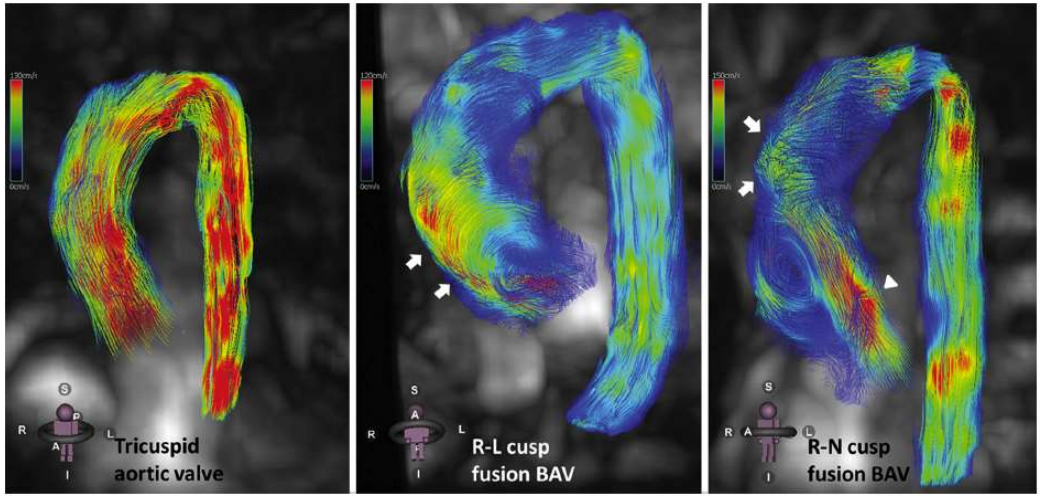

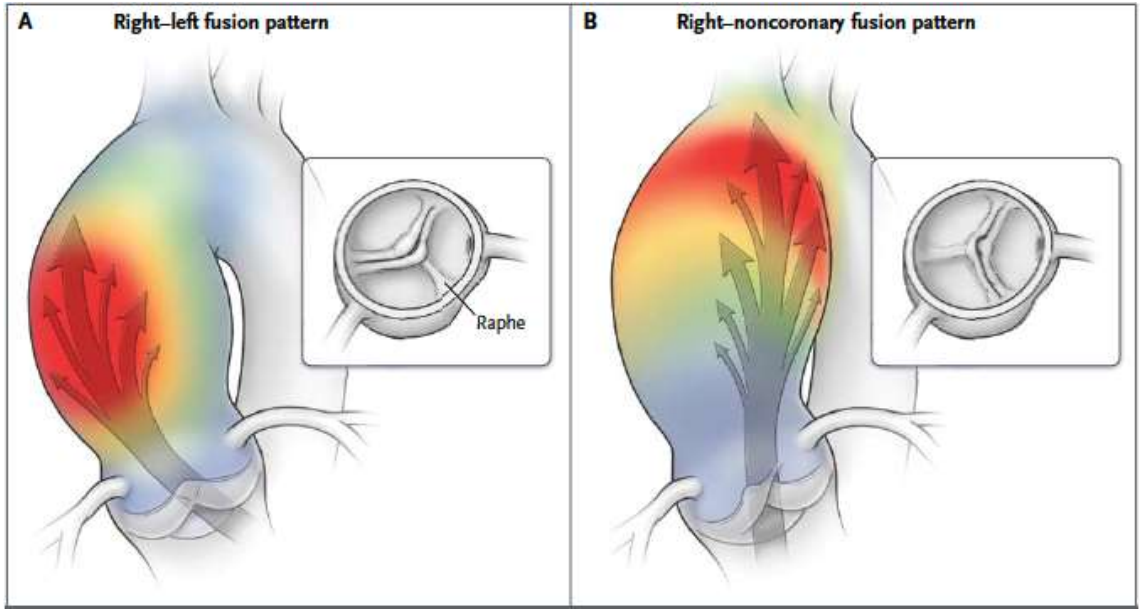

Hôpitaux de Toulouse

Michelena H, et al. *Eur J Cardiothorac Surg.* 2021;60:448-476

Verma S, et al. *N Engl J Med* 2014;370:1920-9

RÉTRÉCISSEMENT AORTIQUE

&

FIBROSE MYOCARDIQUE

Hôpitaux de Toulouse

Diffuse Myocardial Fibrosis and Diastolic Function in Aortic Stenosis

Association Between ECV and Diastolic Function Parameters in the Entire Study Population of Patients With Aortic Stenosis and Control Subjects

	ECV (per 1% Increase)			
	Unadjusted		Adjusted*	
	OR (95% CI)	p Value	OR (95% CI)	p Value
Diastolic dysfunction†	1.15 (1.04–1.27)	0.005	1.15 (1.04–1.26)	0.006
Septal e′ <7 cm/s	1.19 (1.02–1.39)	0.030	1.19 (1.01–1.39)	0.038
E/septal e′ ratio >15	1.16 (1.05–1.27)	0.003	1.15 (1.05–1.27)	0.003
TR Vmax >2.8 m/s	1.12 (0.99–1.27)	0.064	1.12 (0.99–1.27)	0.075
LAVI >34 ml/m^2	1.11 (0.98–1.27)	0.113	1.10 (0.97–1.26)	0.145

Hôpitaux de Toulouse

Lee HJ, et al. *J Am Coll Cardiol Img* 2020;13:2561–72

Diffuse Myocardial Fibrosis and Diastolic Function in Aortic Stenosis

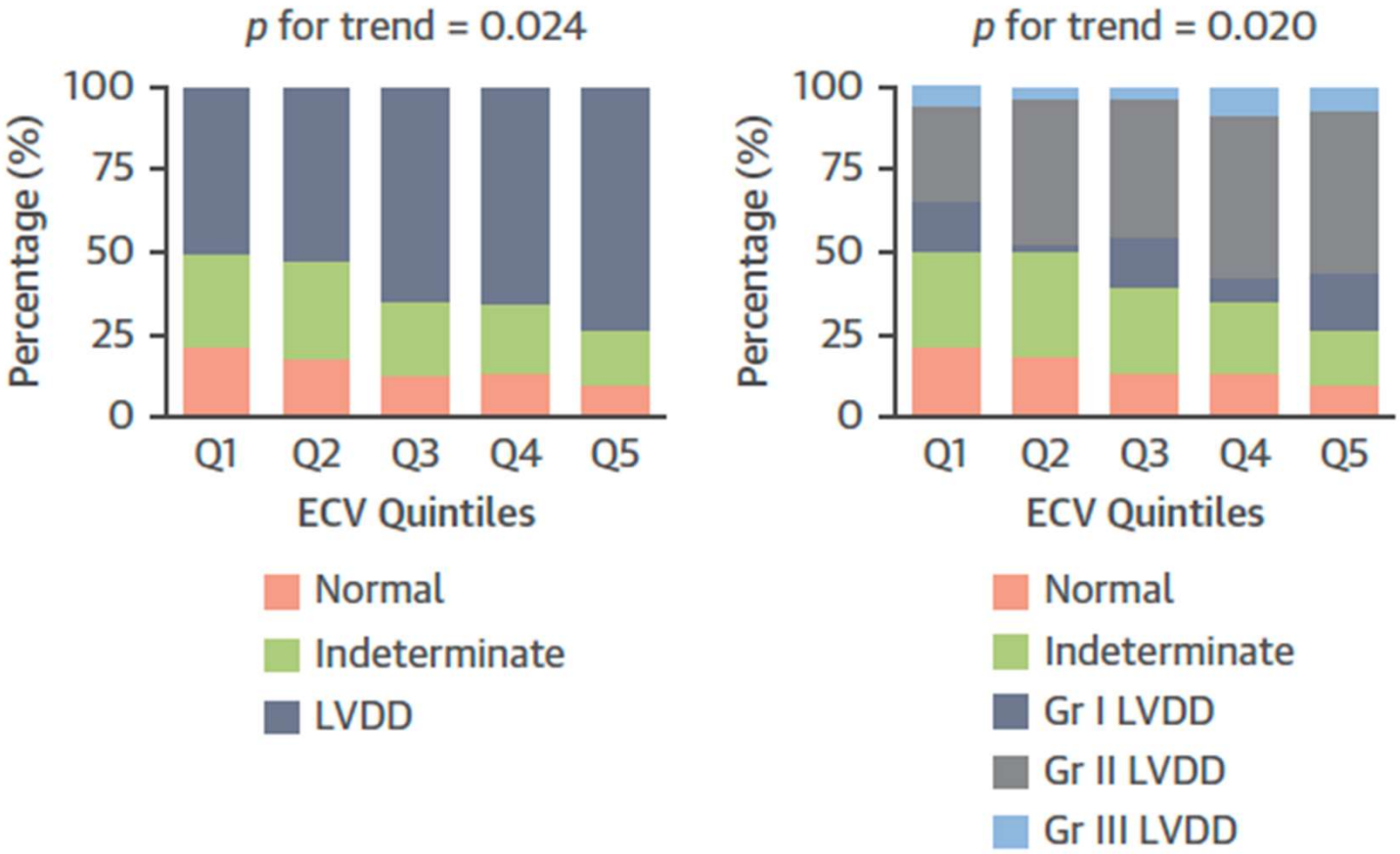

Hôpitaux de Toulouse

Lee HJ, et al. *J Am Coll Cardiol Img* 2020;13:2561–72

Diffuse Myocardial Fibrosis and Diastolic Function in Aortic Stenosis

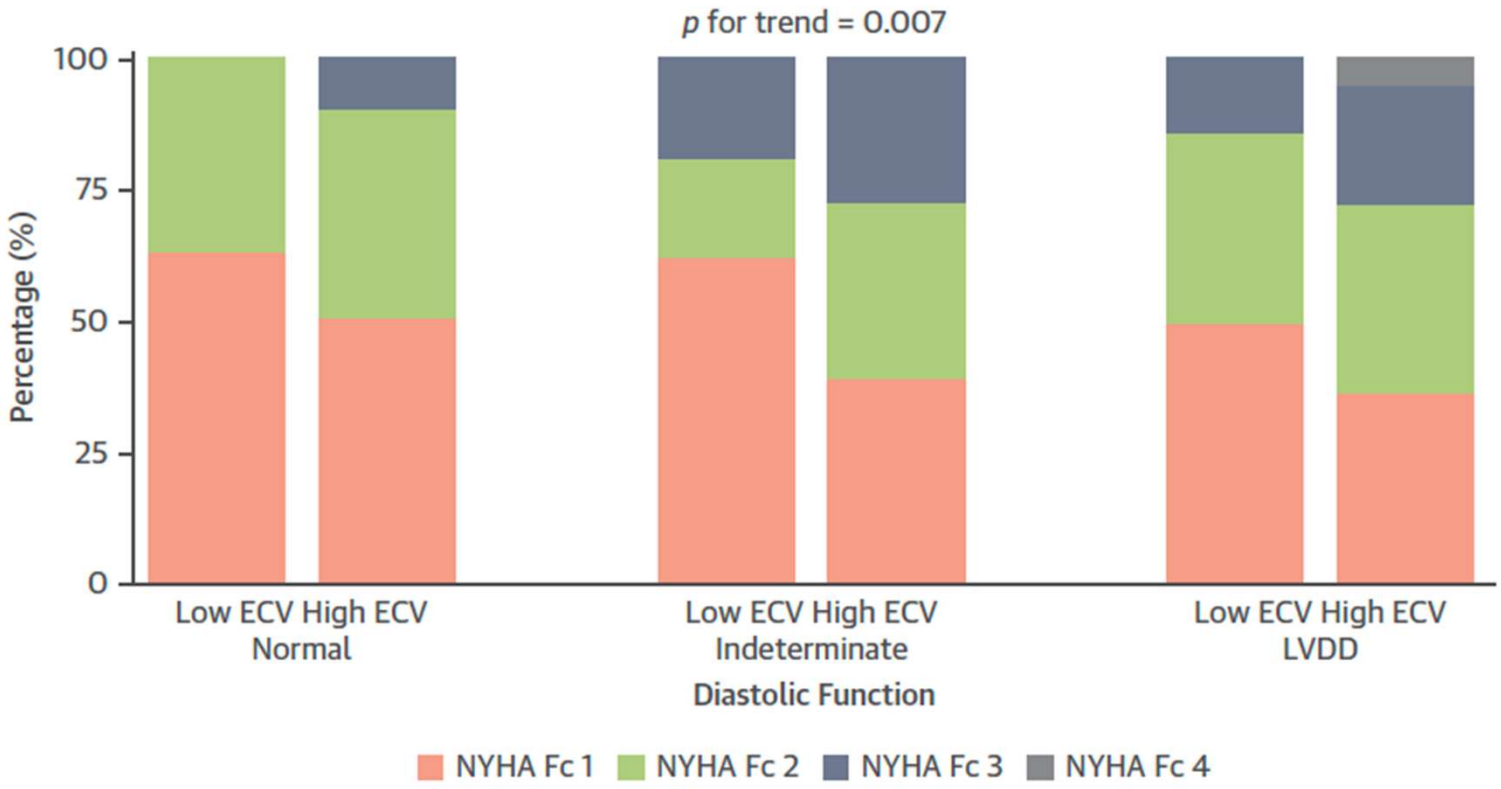

Hôpitaux de Toulouse

Lee HJ, et al. *J Am Coll Cardiol Img* 2020;13:2561–72

Noninvasive Detection of Fibrosis Applying Contrast-Enhanced Cardiac Magnetic Resonance in Different Forms of Left Ventricular Hypertrophy

Relation to Remodeling

	AS (n = 21)
AVA (cm^2)	1.0 ± 0.3
LVOT obstruction (n)	—
EF (%)	70 ± 9
LVMI (g/cm)	1.3 ± 0.3
LVEDVI (ml/cm)	0.9 ± 0.2
LGE (%)	62
%LGE	3 ± 3

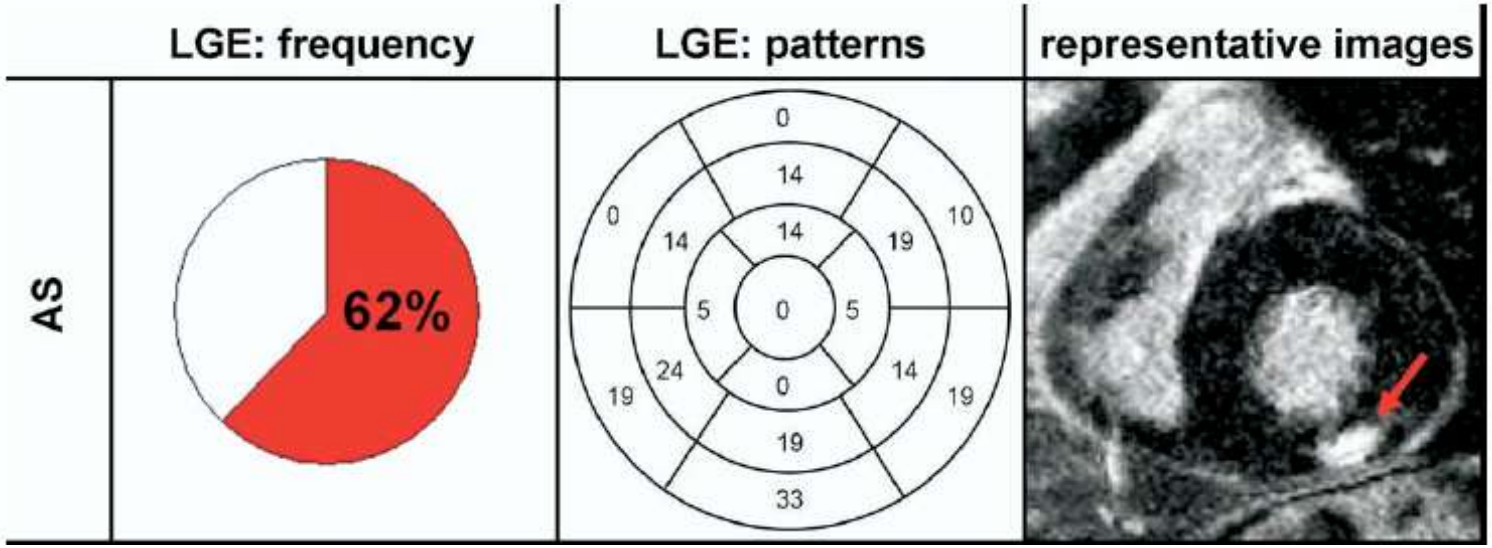

Hôpitaux de Toulouse

Rudolph A, et al. *J Am Coll Cardiol* 2009;53:284–91

Noninvasive Detection of Fibrosis Applying Contrast-Enhanced Cardiac Magnetic Resonance in Different Forms of Left Ventricular Hypertrophy

Relation to Remodeling

	AS (n = 21)
AVA (cm^2)	1.0 ± 0.3
LVOT obstruction (n)	—
EF (%)	70 ± 9
LVMI (g/cm)	1.3 ± 0.3
LVEDVI (ml/cm)	0.9 ± 0.2
LGE (%)	62
%LGE	3 ± 3

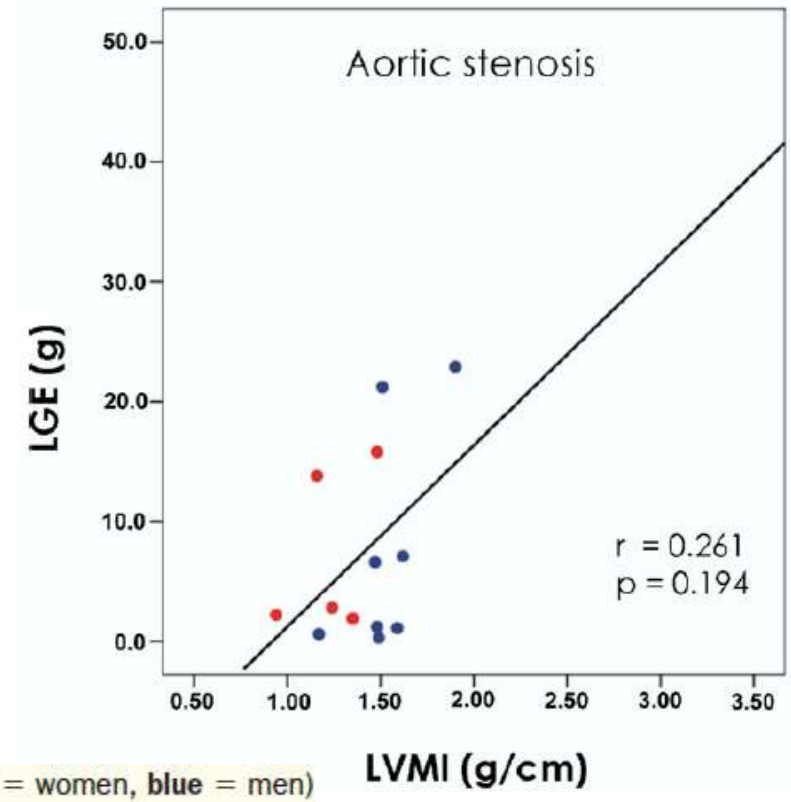

(red = women, blue = men)

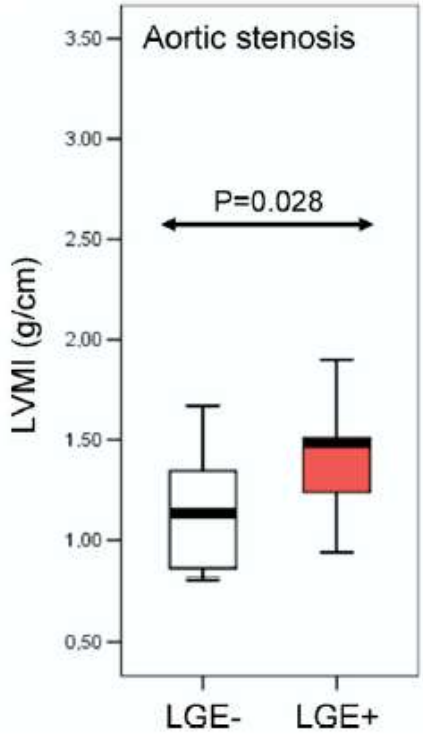

Hôpitaux de Toulouse

Rudolph A, et al. *J Am Coll Cardiol* 2009;53:284–91

Myocardial Scar and Mortality in Severe Aortic Stenosis

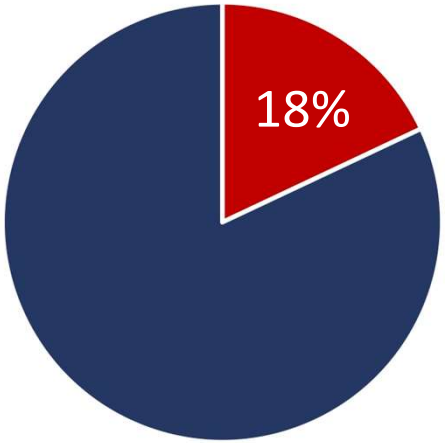

LGE infarct pattern

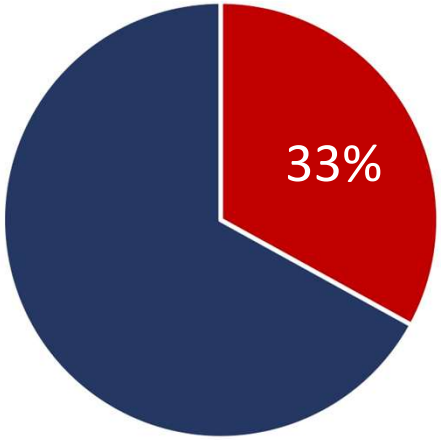

LGE non infarct pattern

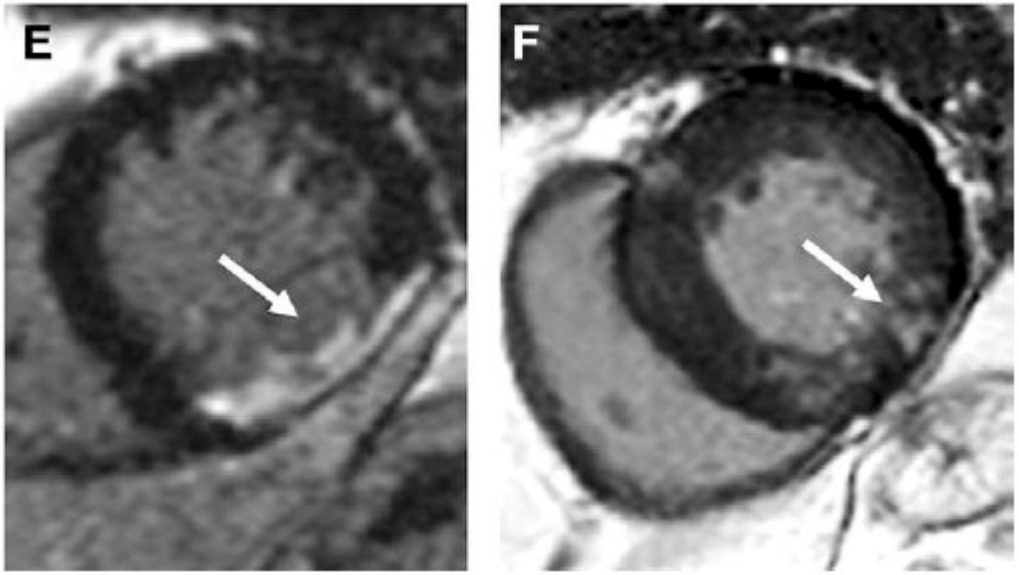

Hôpitaux de Toulouse

Musa T, et al. *Circulation.* 2018;138:1935–1947

HISTOIRE NATURELLE

Hôpitaux de Toulouse

Progression of Hypertrophy and Myocardial Fibrosis in Aortic Stenosis

	Natural History Cohort, n=61	AVR Cohort, n=38
Age, y	61±12	66±8
Male sex, n (%)	40 (66)	29 (76)
Body mass index, kg/m²	28.3±5.6	27.3±3.6
Body surface area, m²	1.88±0.21	1.86±0.16
Echocardiography		
Aortic stenosis severity, n (%)		
Mild	26 (43)	0
Moderate	21 (34)	0
Asymptomatic severe	14 (23)	0
Symptomatic severe	0	38 (100)

LV Assessment	Baseline Values	Annualized Absolute Change, units/y	*P* Value
Indexed left ventricular end-diastolic volume, mL/m²	70±12	−1 (−4, 2)	0.015
Ejection fraction, %	75±8	0 (−2, 4)	0.23
Left ventricular mass index, g/m²	75±20	3 (1, 5)	<0.0001
Maximum left ventricular wall thickness, mm	12±3	0.5 (0, 1)	<0.0001
Infarct late gadolinium enhancement, n (%)	8 (13)	…	…
Infarct late gadolinium enhancement mass, g	7.6±4.5	−0.1 (−1.4, 0.7)	0.56
Midwall late gadolinium enhancement, n (%)	16 (26)	…	…
Midwall late gadolinium enhancement mass, g	2.5 (0.8, 4.8)	1.6 (0.4, 4.1)	<0.0001

Hôpitaux de Toulouse

Everett R, et al. *Circ Cardiovasc Imaging.* 2018;11:e007451

Progression of Hypertrophy and Myocardial Fibrosis in Aortic Stenosis

LV Assessment	Aortic Valve Stenosis Severity			*P* Value
	Mild, n=26	Moderate, n=21	Severe, n=14	
Infarct late gadolinium enhancement, n (%)	2 (8)	3 (14)	3 (21)	…
Midwall late gadolinium enhancement, n (%)	1 (4)	10 (48)	5 (36)	…
T1 mapping measures				
Extracellular volume fraction, %/y	0 (–1.9, 0.8)	0 (–0.8. 1.7)	0 (0.5, 0.9)	0.61
Total extracellular volume, mL/y	0.7 (0.0, 1.0)	1.5 (–0.2, 6.8)	3.7 (0.4, 6.0)	0.08
Indexed extracellular volume, mL/m^2 per year	0.3 (–0.1, 0.6)	0.8 (–0.1, 2.9)	2.0 (0.2, 2.9)	0.07

Hôpitaux de Toulouse

Everett R, et al. *Circ Cardiovasc Imaging.* 2018;11:e007451

Progression of Hypertrophy and Myocardial Fibrosis in Aortic Stenosis

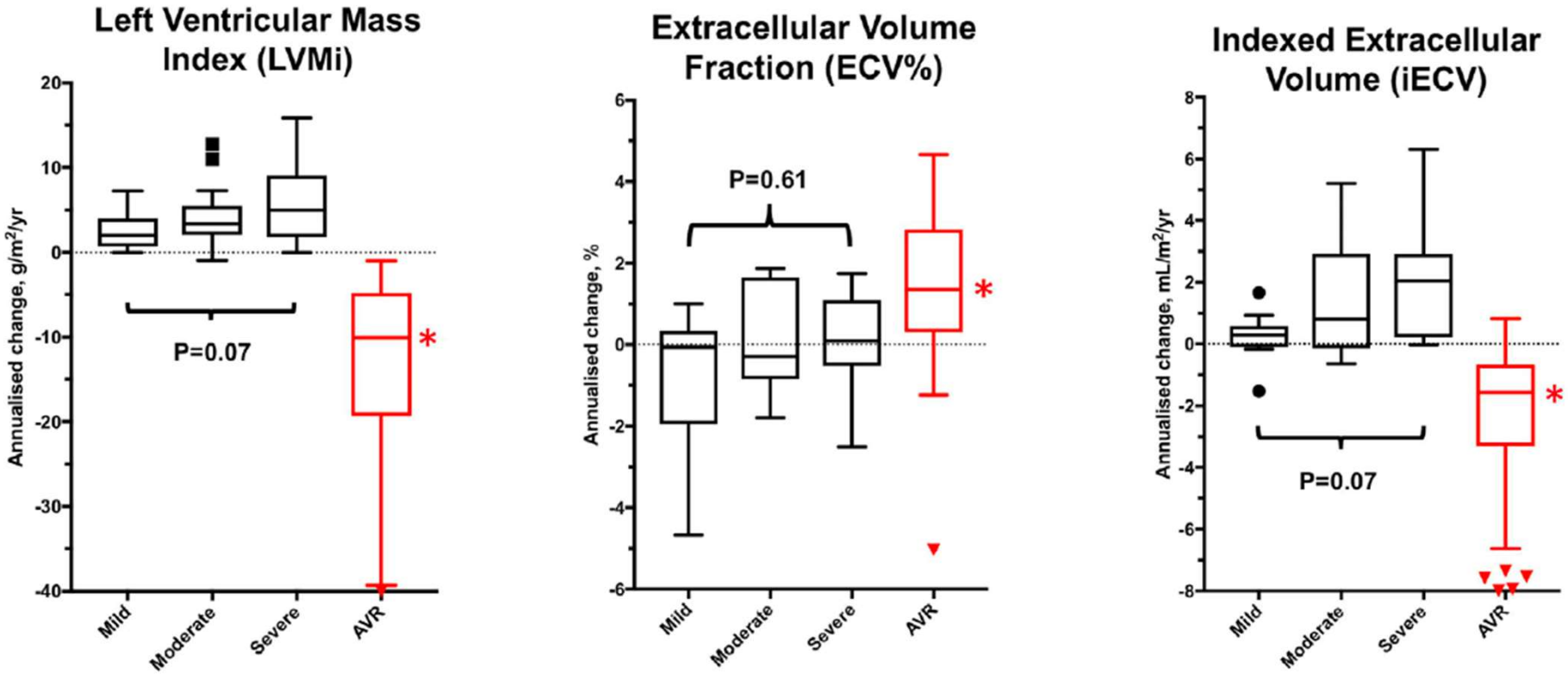

Hôpitaux de Toulouse

Everett R, et al. *Circ Cardiovasc Imaging.* 2018;11:e007451

Progression of Hypertrophy and Myocardial Fibrosis in Aortic Stenosis

Late gadolinium enhancement

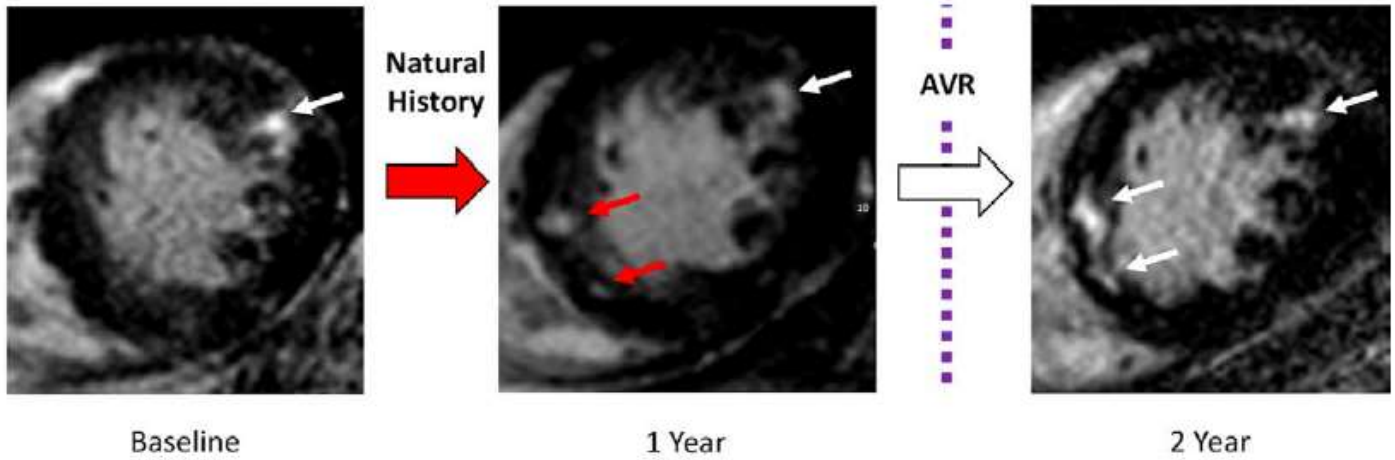

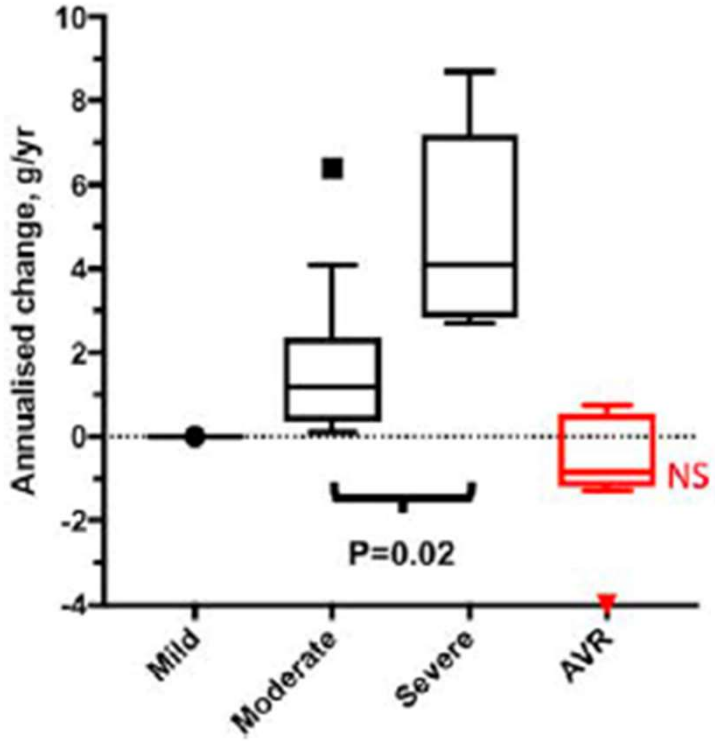

Hôpitaux de Toulouse

Everett R, et al. *Circ Cardiovasc Imaging.* 2018;11:e007451

Progression of Hypertrophy and Myocardial Fibrosis in Aortic Stenosis

Natural History Group

Patient A

V max (m/s)	4.9	5.4
LVMi (g/m²)	148	151
LGE (g)	5.0	13.8
iECV (mL/m²)	42.0	48.4

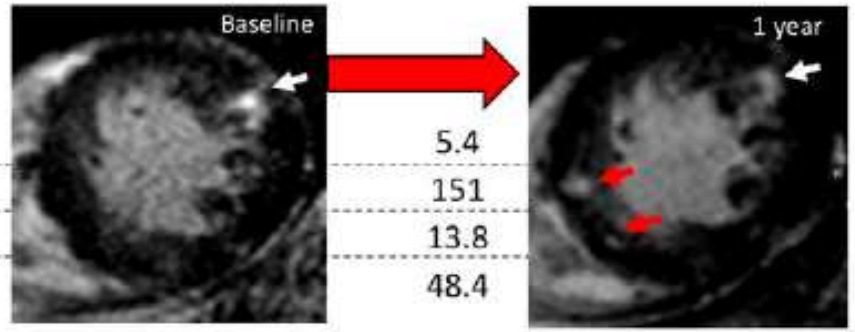

Increasing aortic stenosis severity with time

AVR

AVR Group

Patient B

V max (m/s)	5.3	2.9
LVMi (g/m²)	116	94
LGE (g)	2.6	3.3
iECV (mL/m²)	31.9	23.6

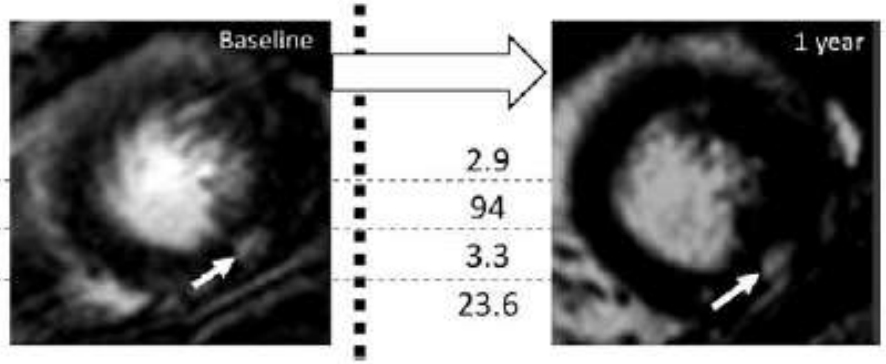

Hôpitaux de Toulouse

Everett R, et al. *Circ Cardiovasc Imaging.* 2018;11:e007451

IMPACT SUR LE PRONOSTIC

Hôpitaux de Toulouse

Diffuse Myocardial Fibrosis and Diastolic Function in Aortic Stenosis

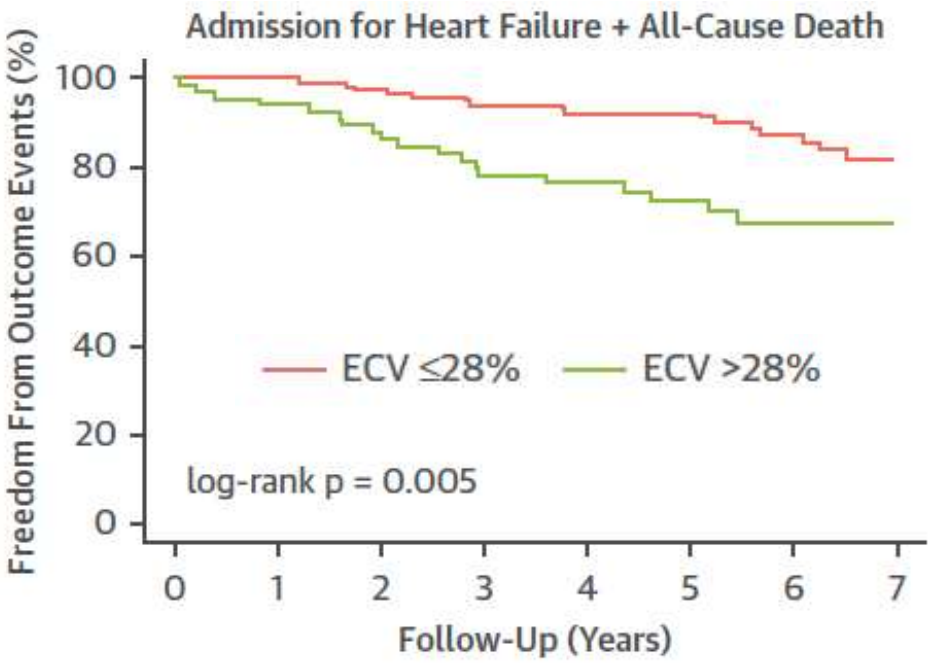

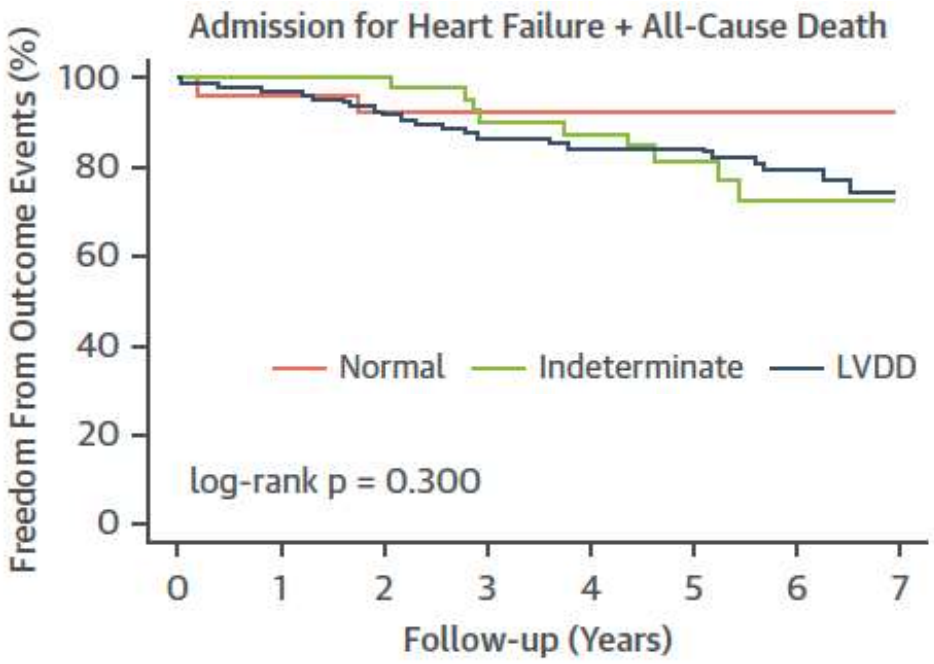

Hôpitaux de Toulouse

Lee HJ, et al. *J Am Coll Cardiol Img* 2020;13:2561–72

Myocardial Scar and Mortality in Severe Aortic Stenosis

Cardiovascular Mortality

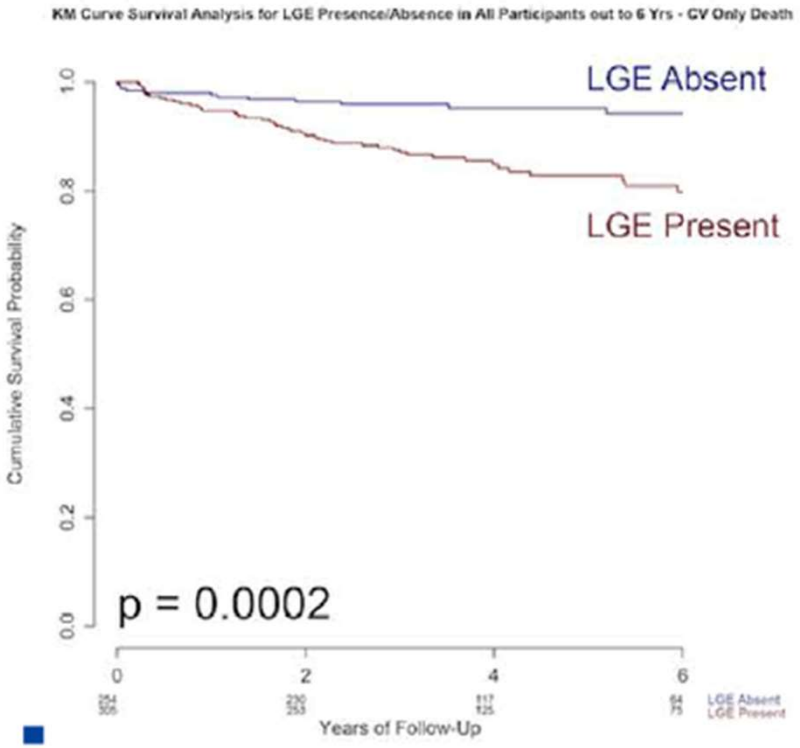

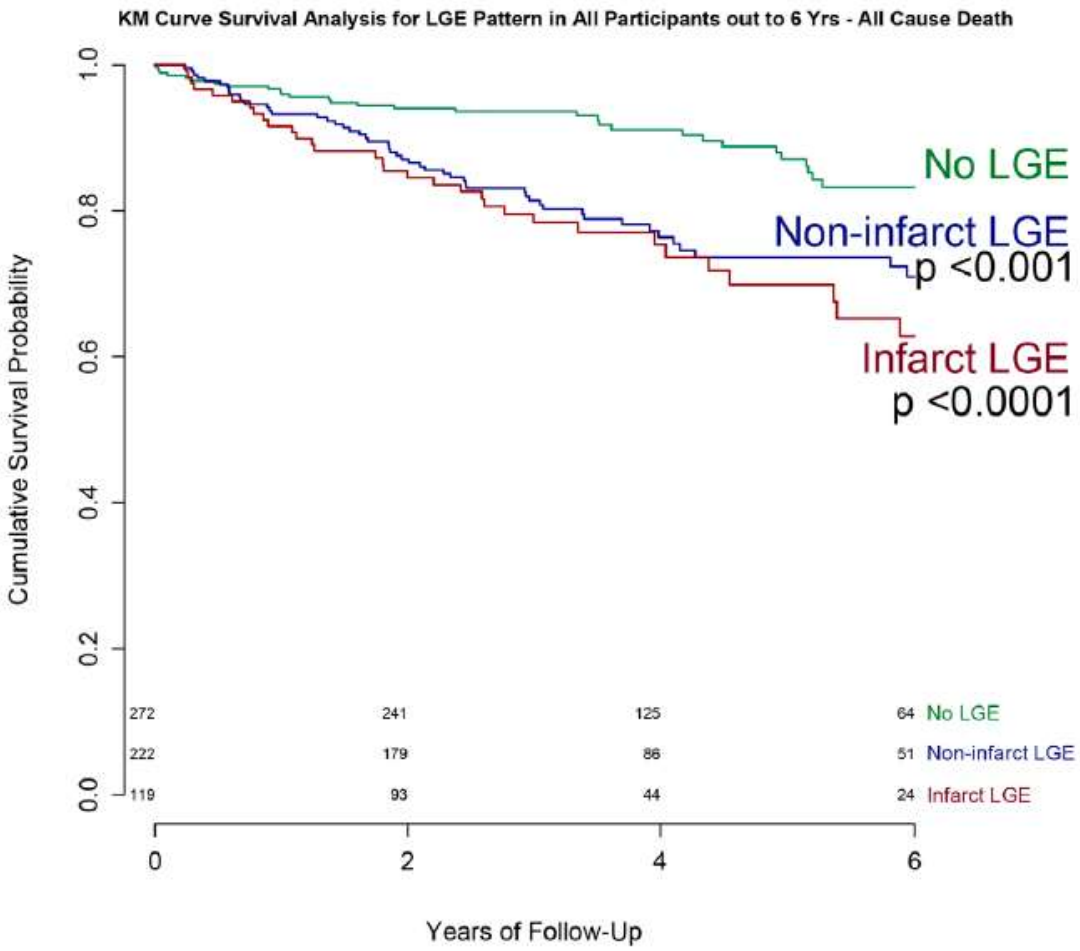

Musa T, et al. *Circulation.* 2018;138:1935–1947

Hôpitaux de Toulouse

Prognostic value of cardiac magnetic resonance in patients with aortic stenosis: A systematic review and meta-analysis

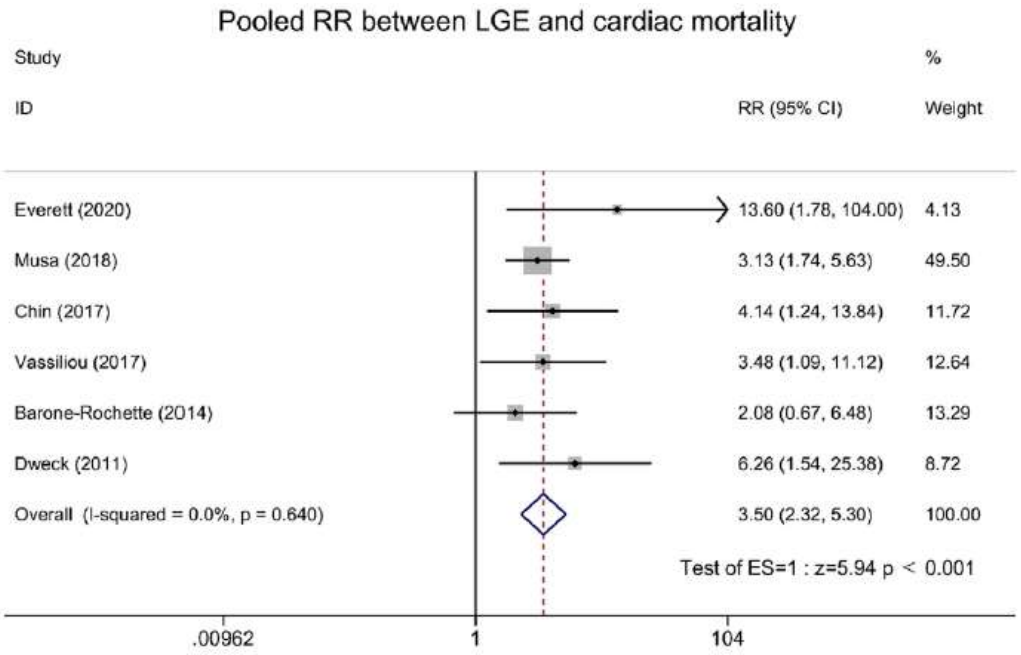

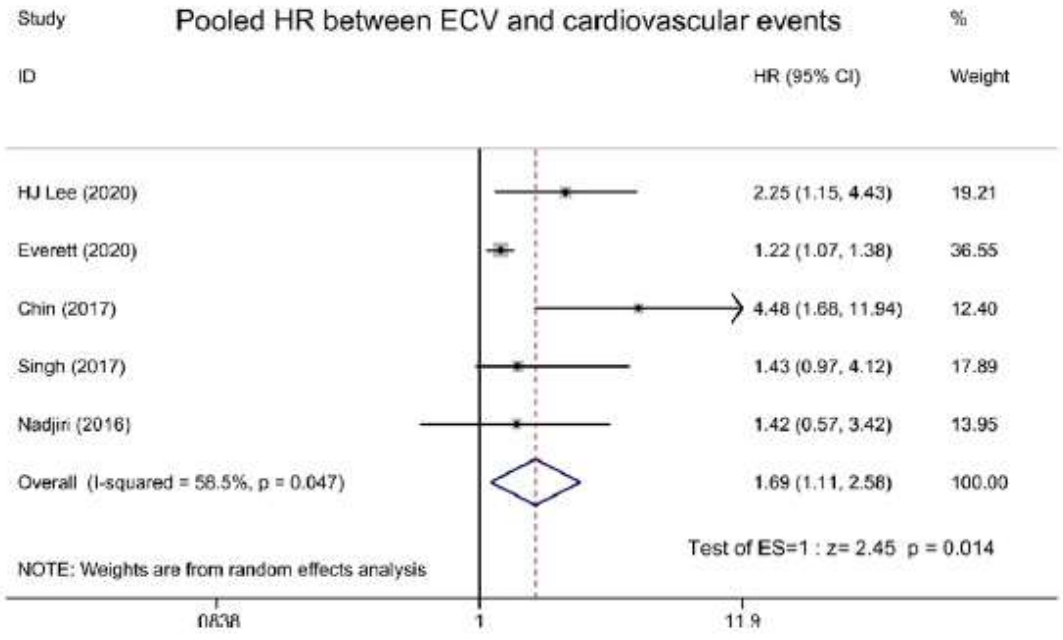

Hôpitaux de Toulouse

Zhang C, et al. *PLoS One.* 2022;17:e0263378

LA PLACE DE L'AMYLOSE

Hôpitaux de Toulouse

Senile systemic amyloidosis affects 25% of the very aged: A population-based autopsy study

Population finlandaise
256 autopsies de sujets de plus de 85 ans
Âge de 85 à 106 ans (moyenne 93 ans)

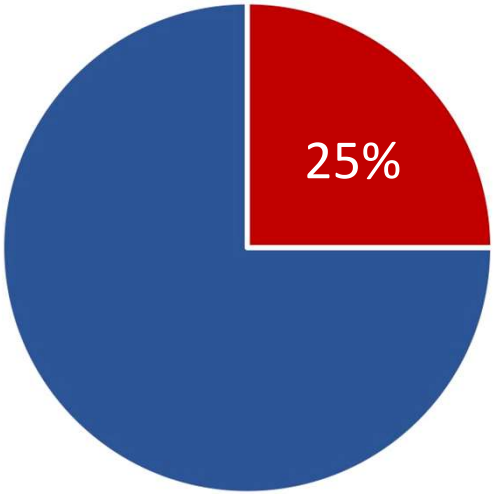

Amylose cardiaque à transthyrétine :

- 25% (63/256) de la population de l'étude

- 17% (11/65) des 85–89 ans
- 23% (29/127) des 90–94 ans
- 32% (18/56) des 95–100 ans
- 63% (5/8) des > 100 ans

Hôpitaux de Toulouse

Tanskanen M, et al. *Ann Med.* 2008;40:232-9

PRÉVALENCE DU RAO DANS L'AMYLOSE CARDIAQUE

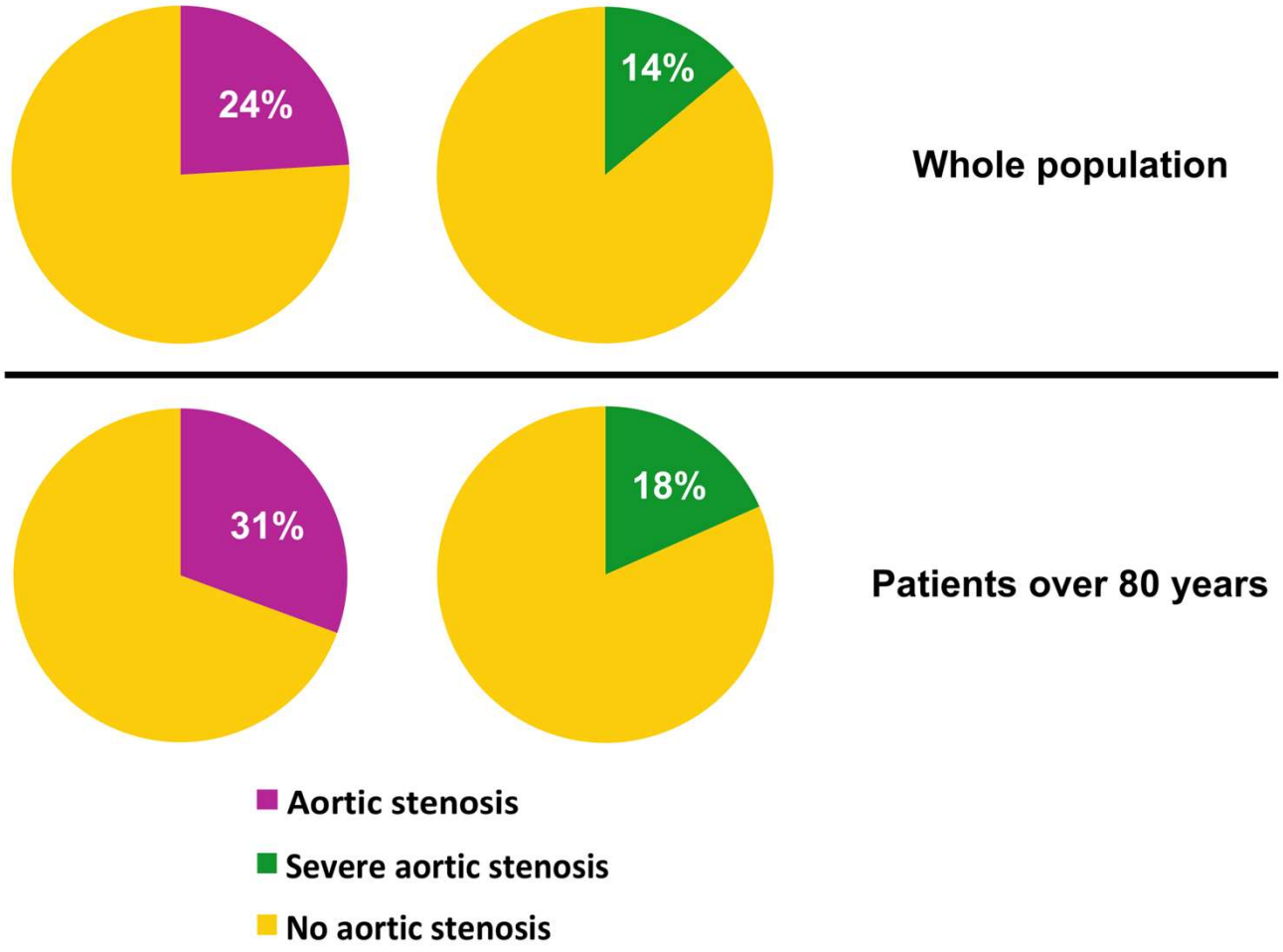

Hôpitaux de Toulouse

Cavaillerie, et al. En cours

Cardiac amyloidosis is prevalent in older patients with aortic stenosis and carries worse prognosis

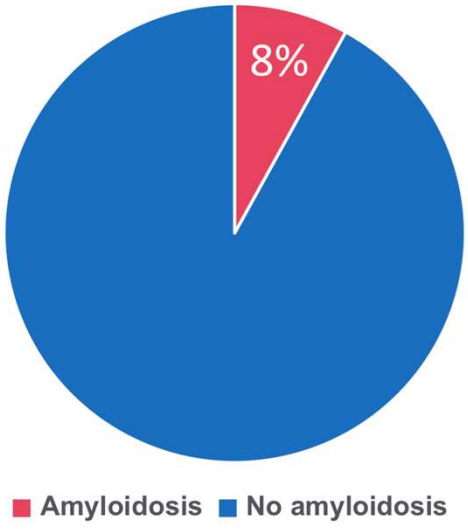

Population totale
(n=113)

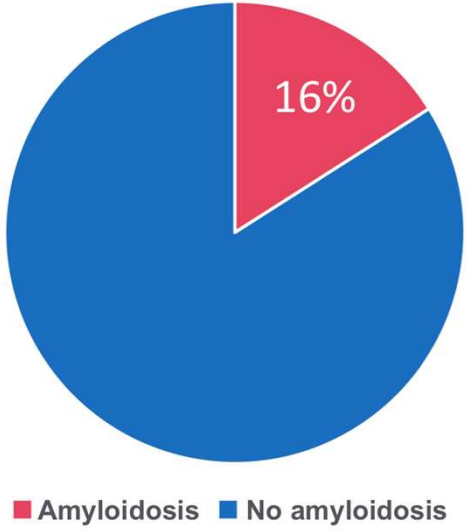

Patients > 74 ans
(n=57)

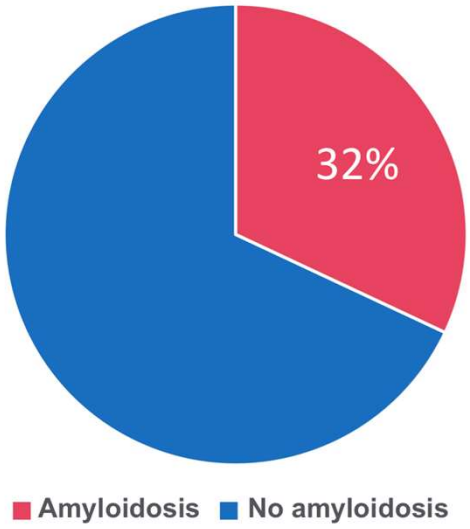

Hommes > 74 ans
(n=25)

Hôpitaux de Toulouse

Cavalcante JL, et al. *J Cardiovasc Magn Reson* 2017;19:98

Cardiac amyloidosis is prevalent in older patients with aortic stenosis and carries worse prognosis

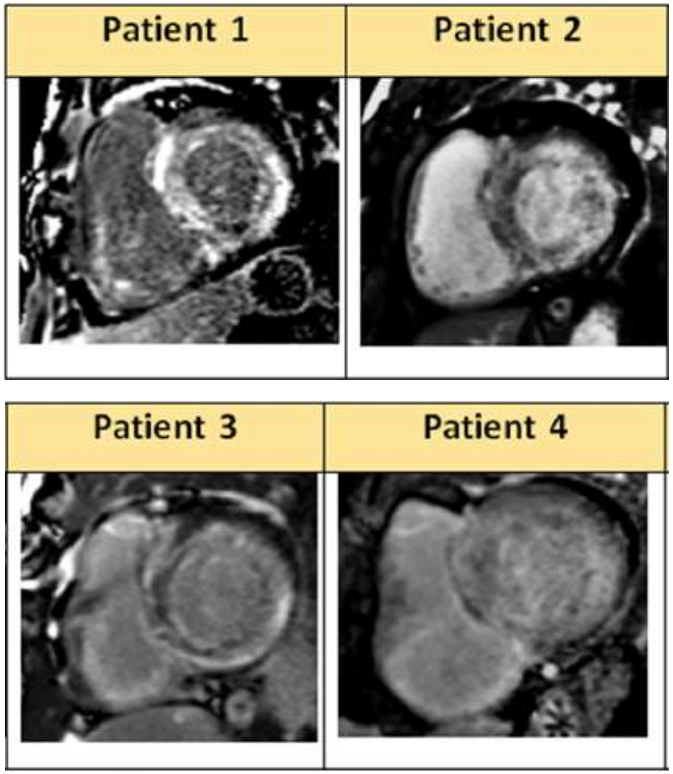

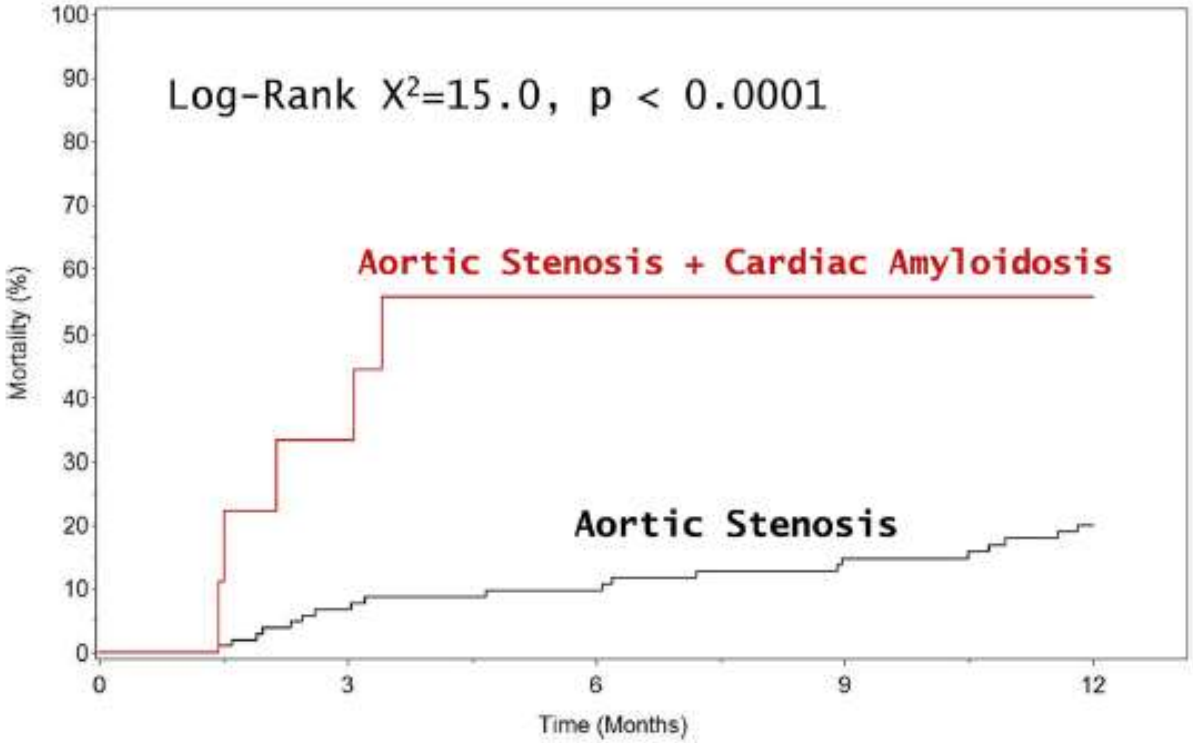

Hôpitaux de Toulouse

Cavalcante JL, et al. *J Cardiovasc Magn Reson* 2017;19:98

Synthèse
Rétrécissement aortique & fibrose myocardique en IRM

Hôpitaux de Toulouse

PHYSIOPATHOLOGIE

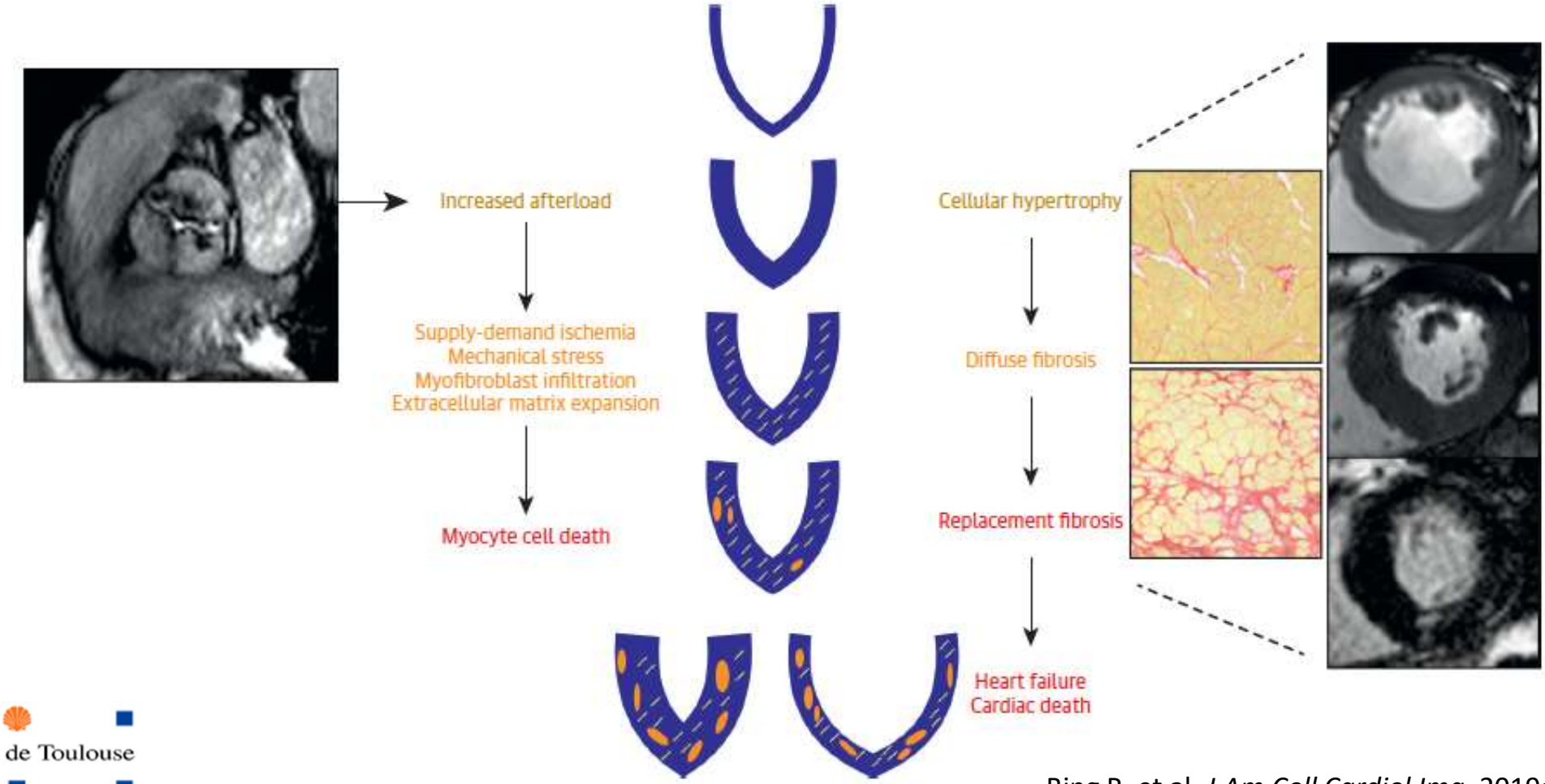

Hôpitaux de Toulouse

Bing R, et al. *J Am Coll Cardiol Img*. 2019;12:283–96

PRÉVALENCE & SÉMIOLOGIE

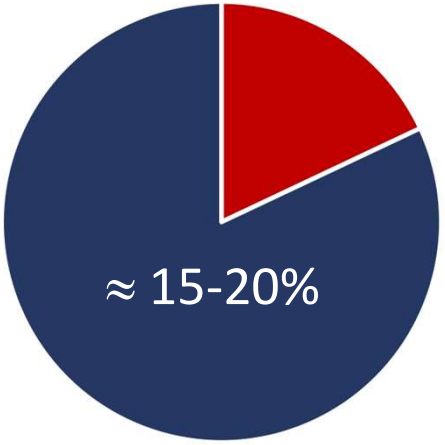

LGE infarct pattern

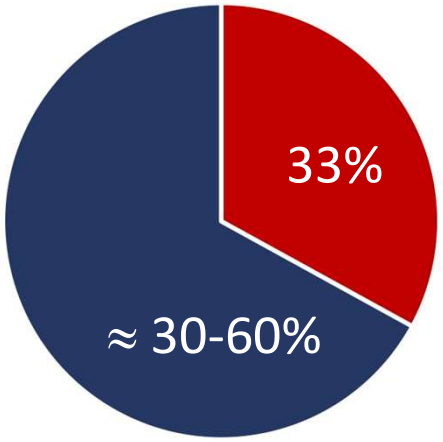

LGE non infarct pattern

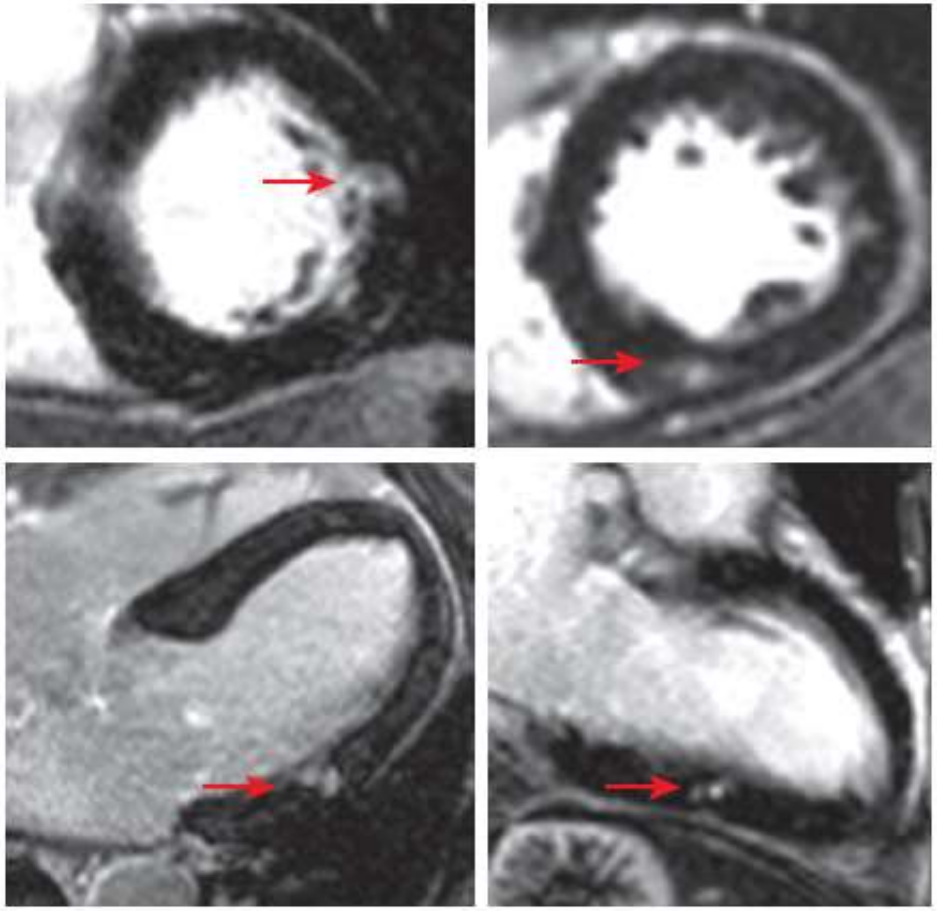

Hôpitaux de Toulouse

PRONOSTIC

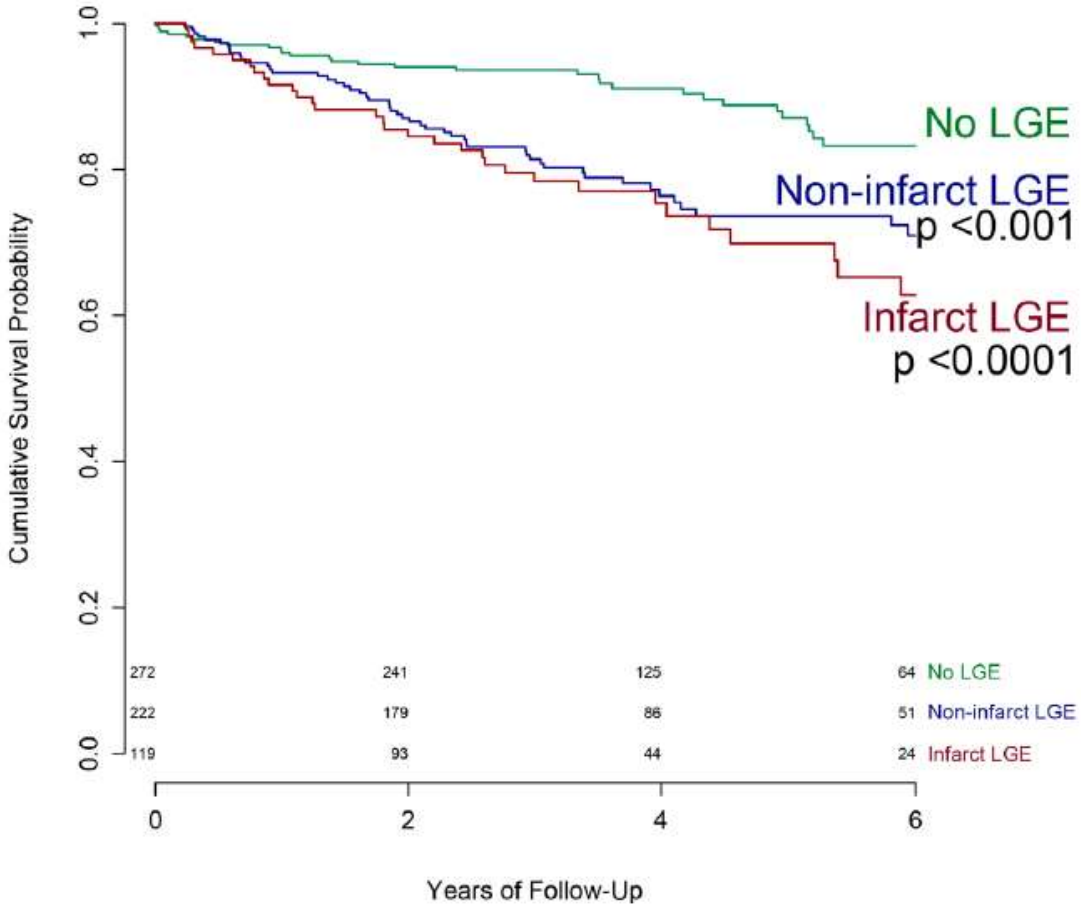

Hôpitaux de Toulouse

Musa T, et al. *Circulation.* 2018;138:1935–1947

HISTOIRE NATURELLE

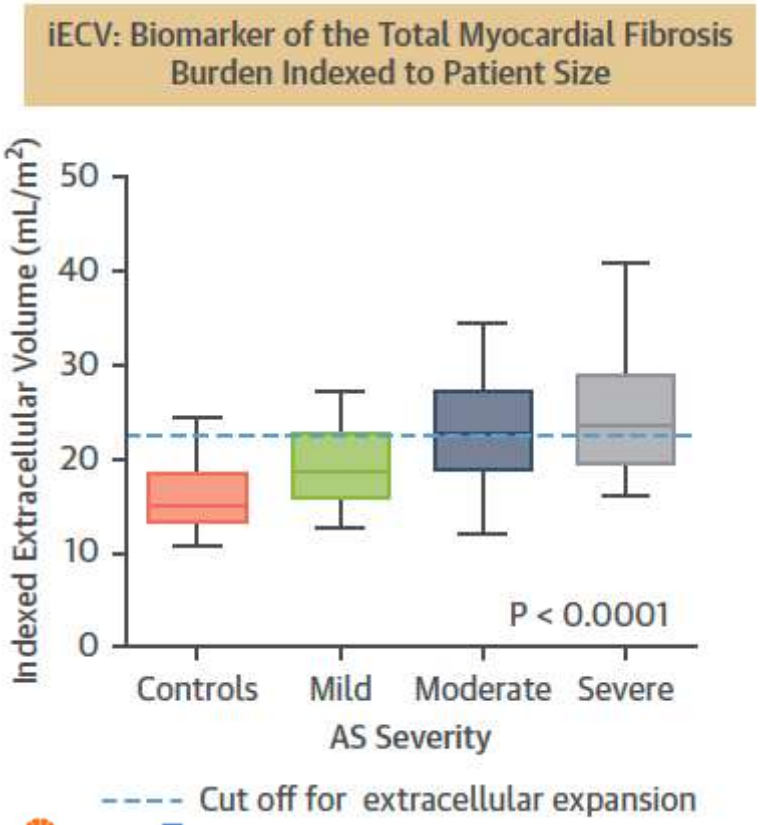

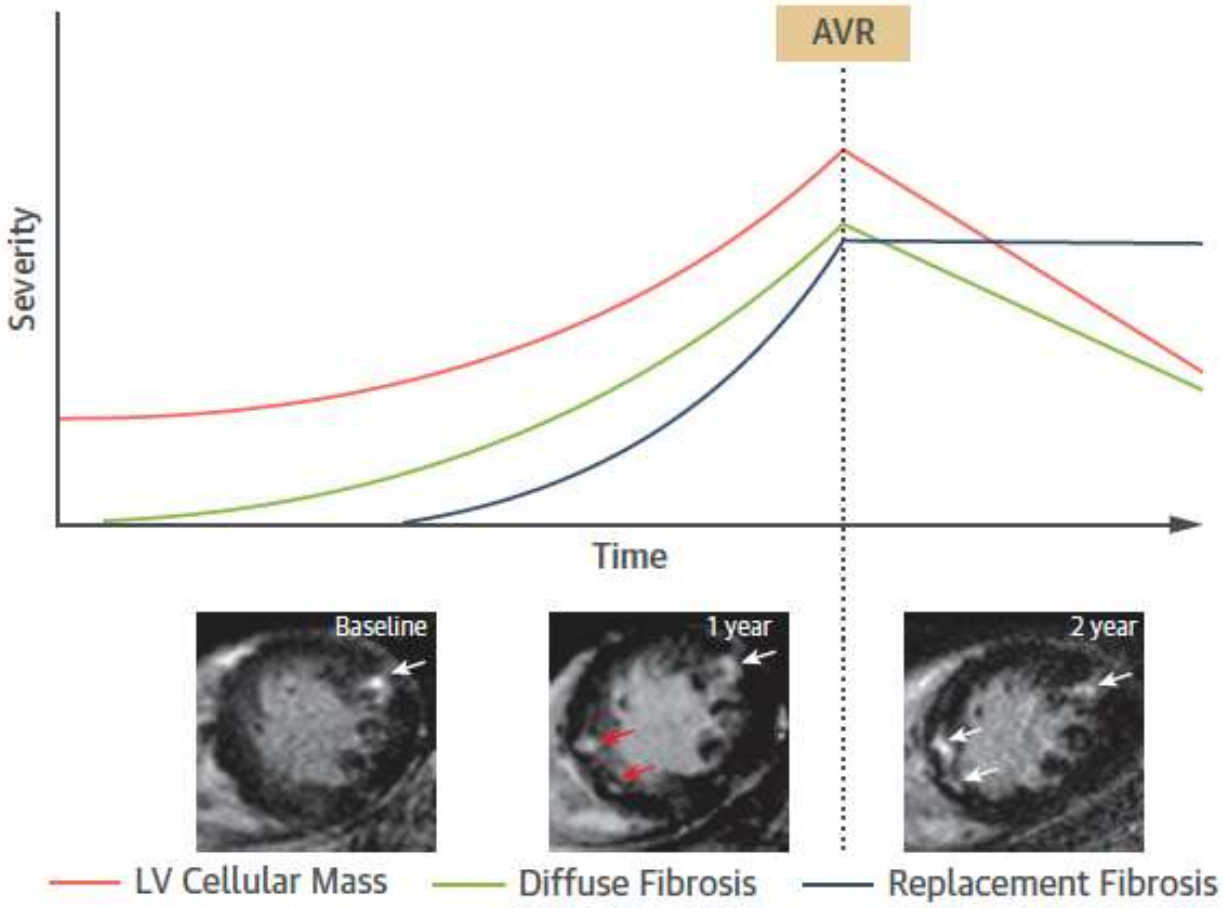

Hôpitaux de Toulouse

Bing R, et al. *J Am Coll Cardiol Img*. 2019;12:283–96

PERSPECTIVES

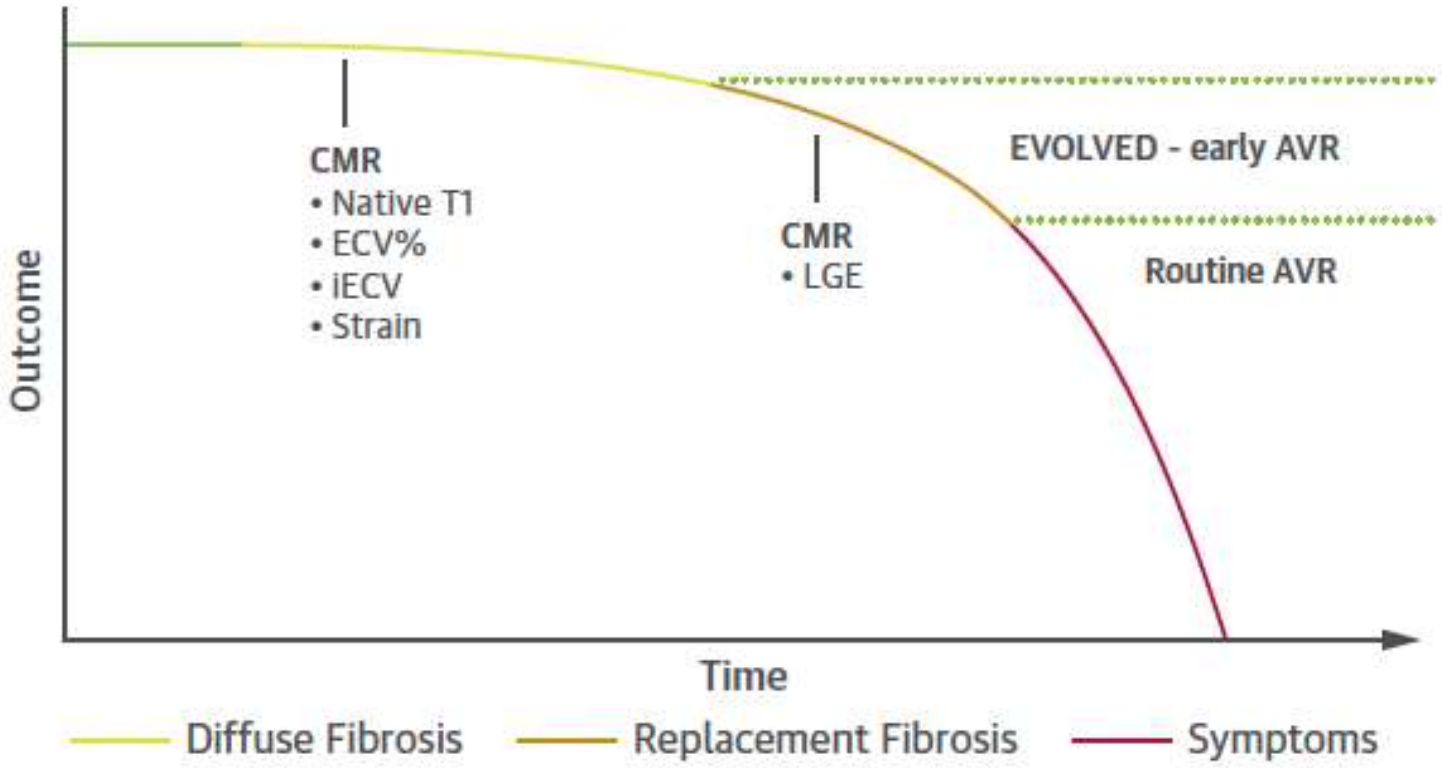

Hôpitaux de Toulouse

Bing R, et al. *J Am Coll Cardiol Img*. 2019;12:283–96